

*Department of
Radiology
Techniques
The Second Stage*



Humerus

Lecture 5

Assist. Lecturer

Tariq Nadhim Jassim

Fadhil Aad Leftah Al-zurfi

Basic Projections of Humerus

Two Positions

1- Anterior - Posterior (AP) Supine and Erect

Position

2- Lateral

Cassette Out Bucky (14 x 17 inches).

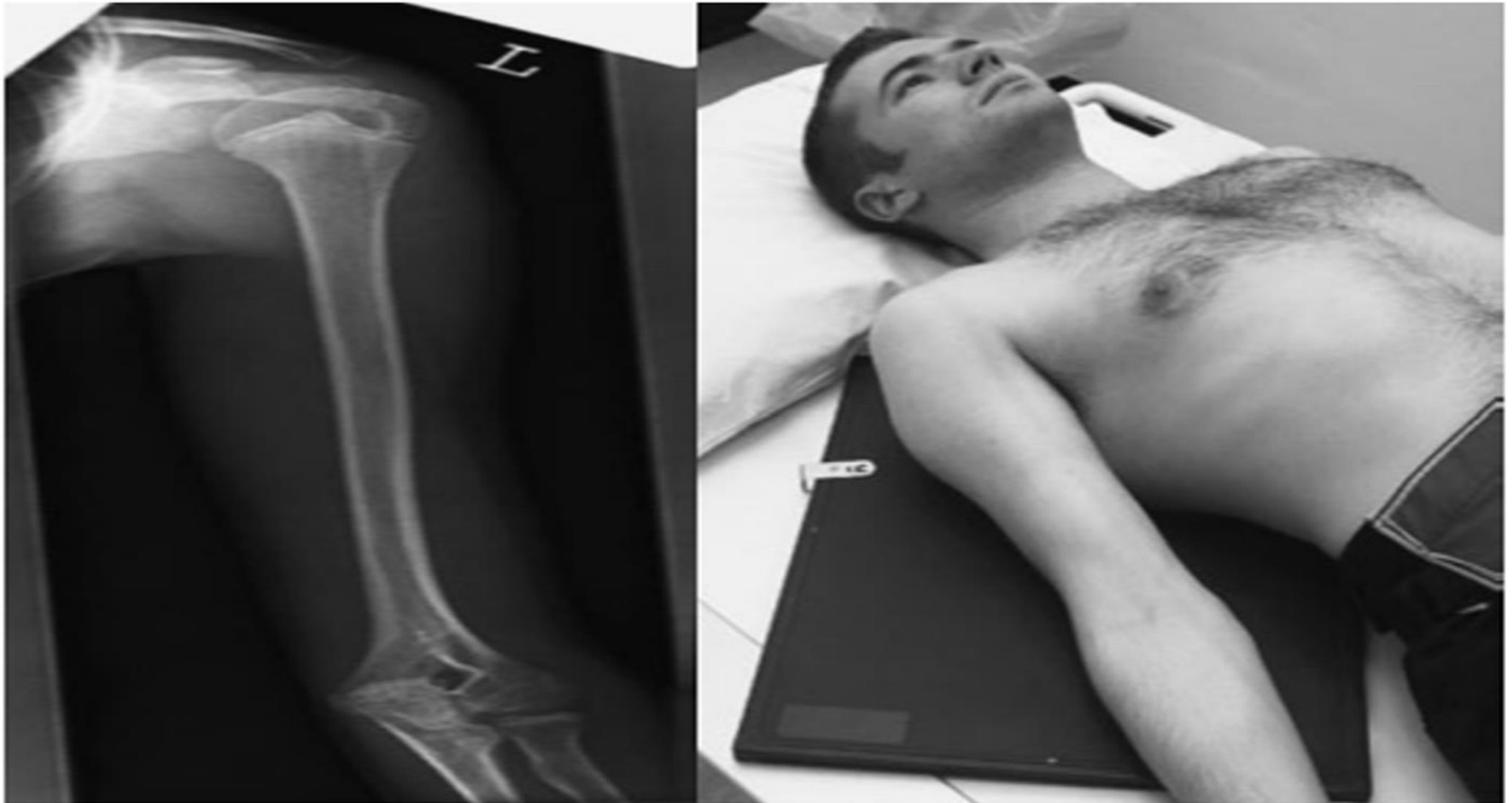1- Anterior - Posterior (AP) Supine Position

Position of Patient

- The patient lies supine on the X-ray table, with the unaffected side raised and supported on pads.
- The cassette is positioned out bucky under the affected limb and adjusted to include the shoulder and elbow joints.
- The arm is slightly abducted and the elbow joint is fully extended, so that the posterior aspect of the upper arm is in contact with the cassette.
- The arm is adjusted to ensure that the medial and lateral epicondyles are equidistant from the cassette.
- The forearm is immobilized using a sandbag.

Direction and centering of the X-ray beam

- The vertical central ray is centered to a point midway between the shoulder and elbow joints.



Normal antero-posterior radiograph of humerus

2- Lateral Supine Position

Position of Patient

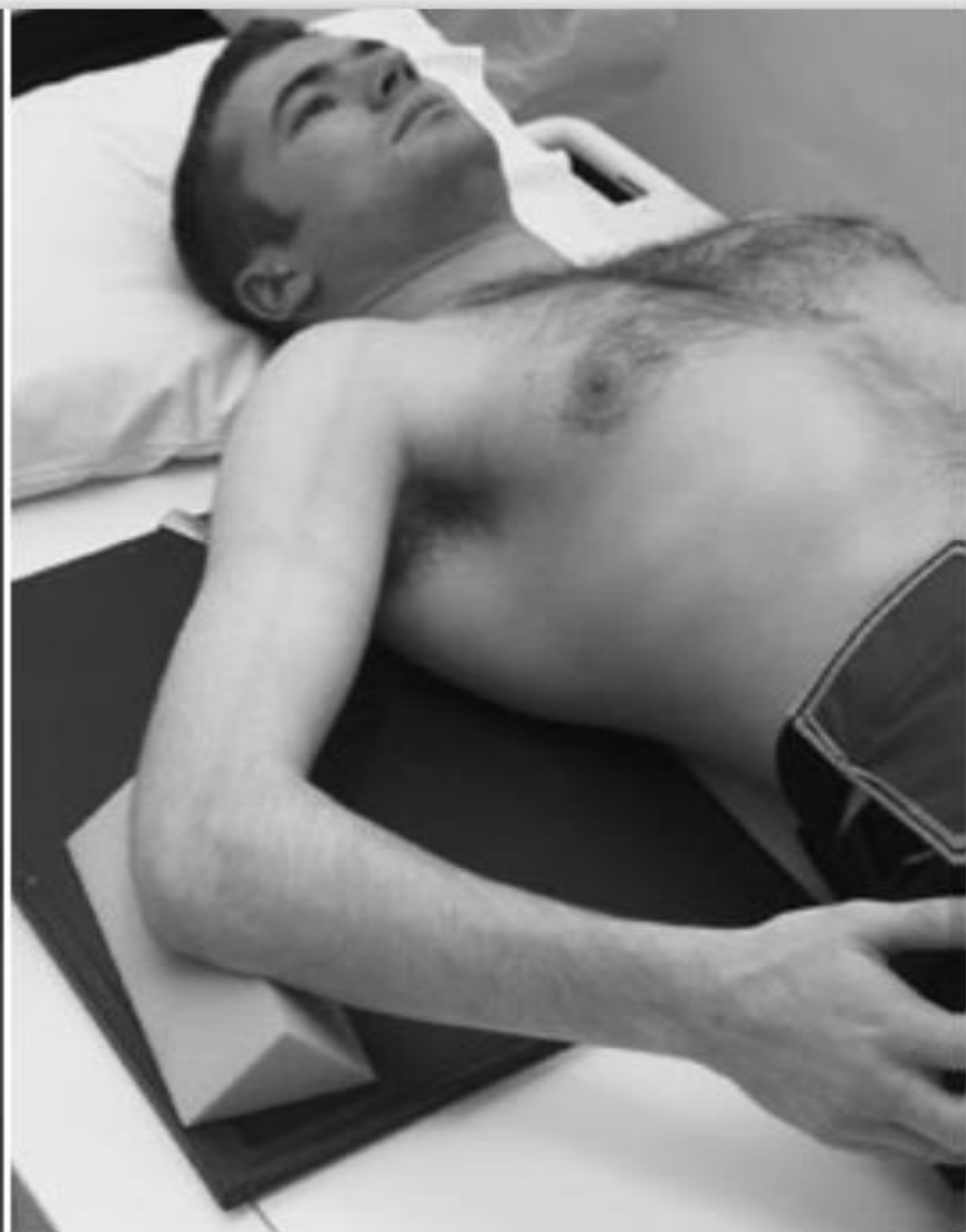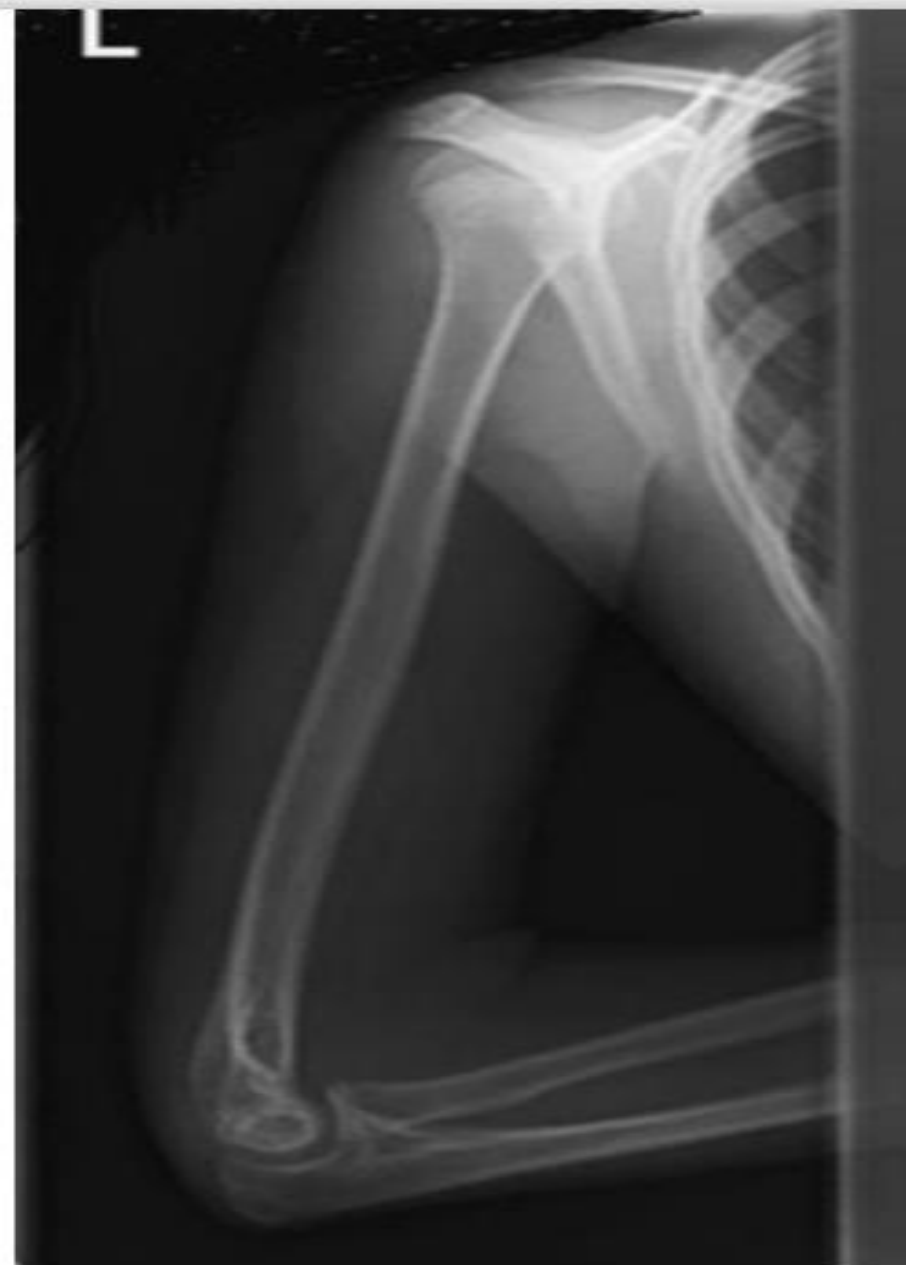- From the antero-posterior position, the elbow joint is flexed to 90 degrees.
- The arm is abducted and then medially rotated through 90 degrees to bring the medial aspect of the arm, elbow and forearm in contact with the table.
- The cassette is placed under the arm and adjusted to include both the shoulder and the elbow joints.
- The humerus is adjusted to ensure that the medial and lateral epicondyles of the humerus are superimposed.
- The forearm is immobilized using a sandbag.

Centering of the X-ray beam

- The vertical central ray is centered to a point midway between the shoulder and elbow joints.

Image Characteristics

- Both joints should be seen on the image.
- The elbow joint should be seen in the true lateral and antero-posterior positions.



Normal lateral radiograph of humerus

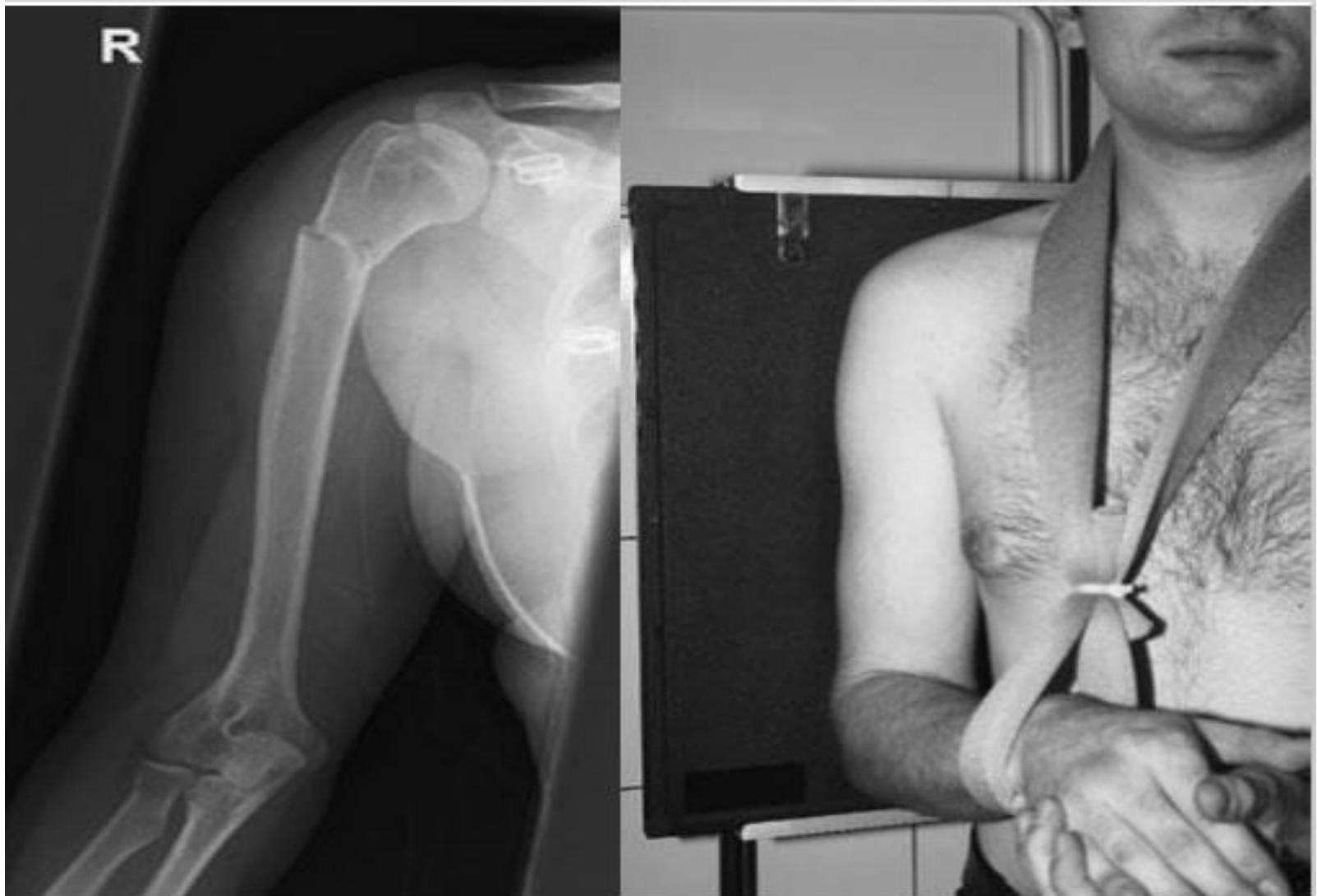1- Anterior - Posterior (AP) Erect Position

Position of Patient

- The cassette is placed in an erect cassette holder.
- The patient sits or stands with their back in contact with the cassette.
- The patient is rotated towards the affected side to bring the posterior aspect of the shoulder, upper arm and elbow into contact with the cassette.
- The position of the patient is adjusted to ensure that the medial and lateral epicondyles of the humerus are equidistant from the cassette .

Direction and Centering of the X-ray beam

- The central ray is directed at right-angles to the shaft of the humerus and centered midway between the shoulder and elbow joints.



Antero-posterior radiograph of humerus showing a fracture of the proximal shaft of the humerus

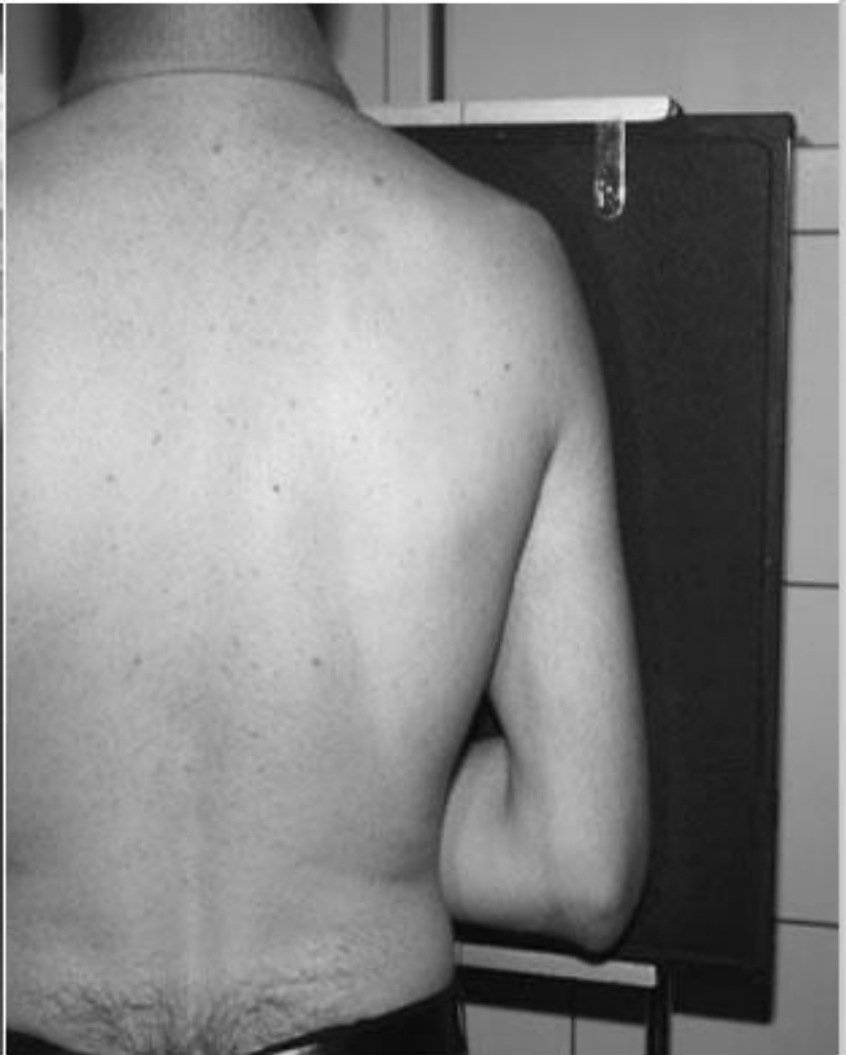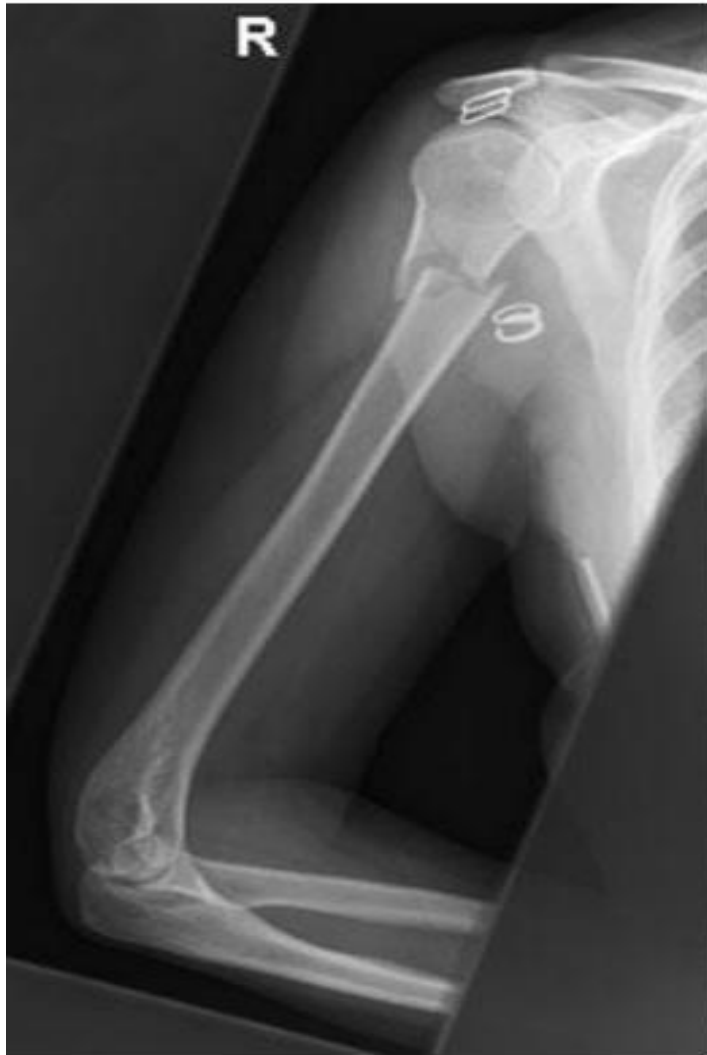2- Lateral Erect Position

Position of Patient

- The cassette is placed in an erect cassette holder.
- From the anterior position, the patient is rotated through 90 degrees until the lateral aspect of the injured arm is in contact with the cassette.
- The patient is now rotated further until the arm is just clear of the rib cage but still in contact with the cassette.

Direction and Centering of the X-ray beam

- The horizontal central ray is directed at right-angles to the shaft of the humerus and centered midway between the shoulder and elbow joint.



Lateral radiograph of the humerus in the same patient

Humerus – neck

1- Anterior - Posterior (AP)

2- Axial or lateral

Cassette Out Bucky (10 x 12 inches).

1- Anterior - Posterior (AP)

Position of Patient

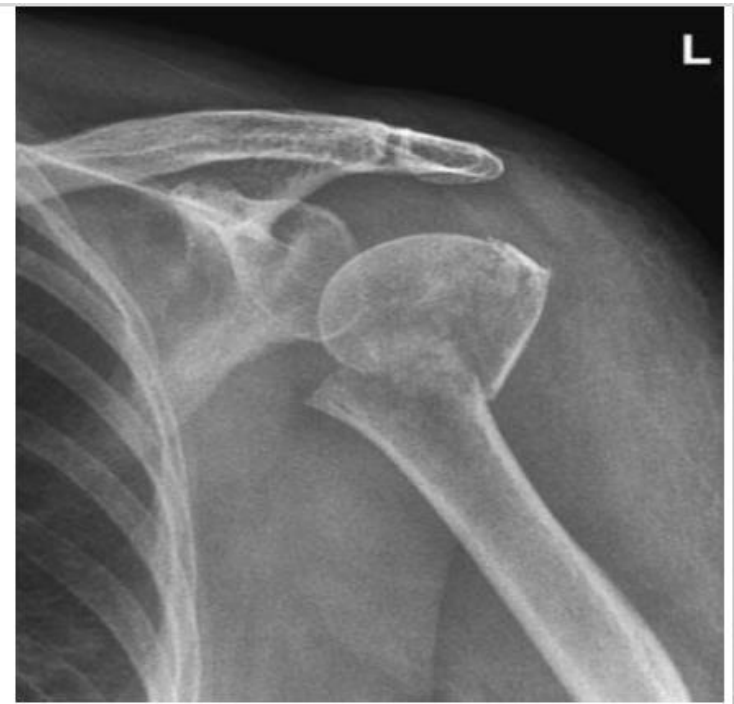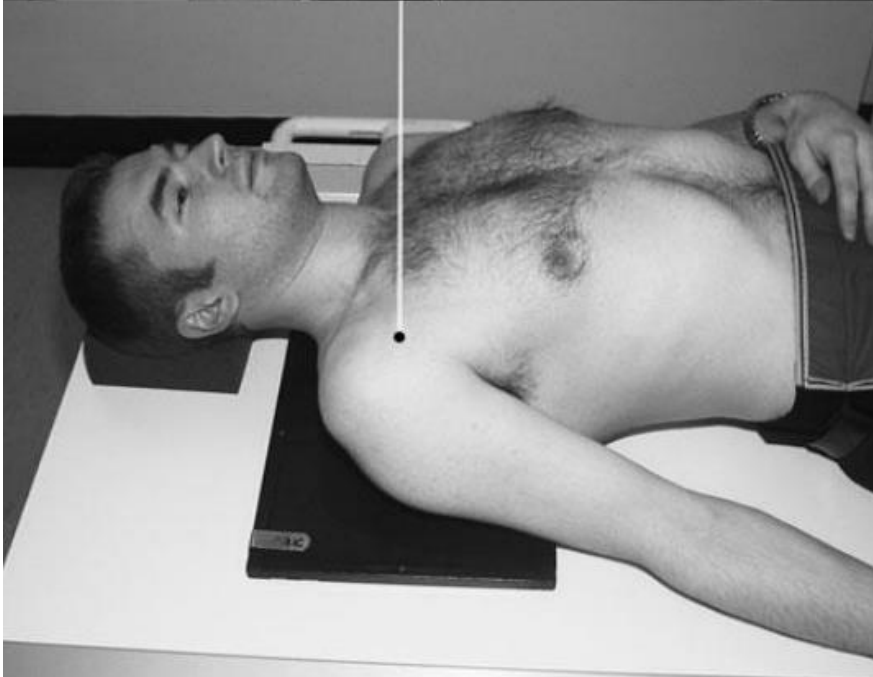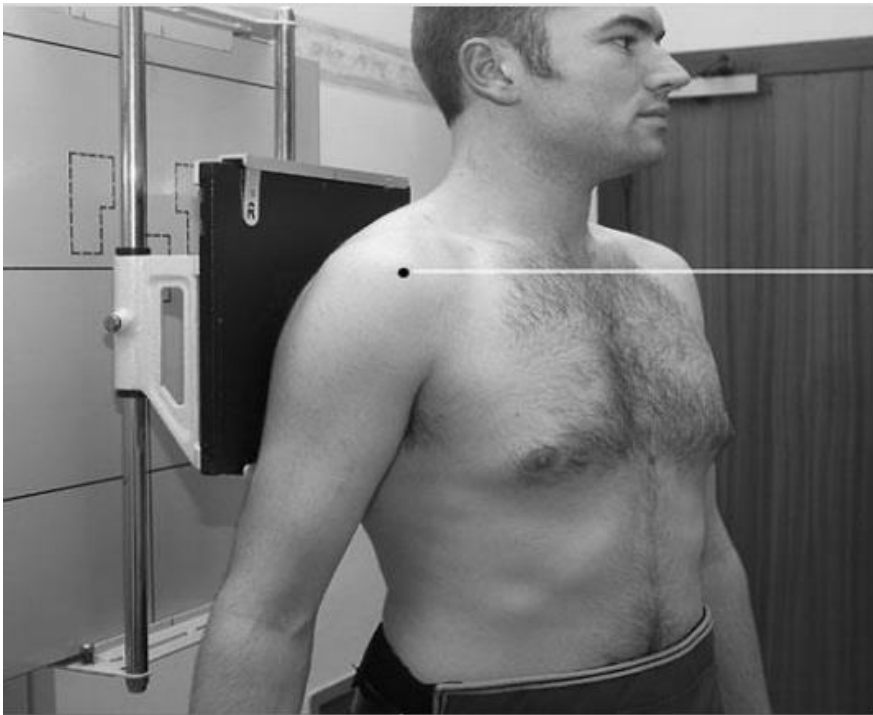
- The patient stands or lies supine facing the X-ray tube.
- The patient is rotated towards the affected side to bring the posterior aspect of the injured shoulder into contact with the midline of the cassette.
- The cassette is positioned out bucky to include the acromion process and the proximal half of the humerus.

Direction and Centering of the X-ray beam

- The central ray is directed at right-angles to the humerus and centered to the head of the humerus.

Essential image characteristics

- The image should include acromion process and proximal half of shaft humerus.
- Should demonstrate adequately the neck of the humerus clear of the thorax.



Antero-posterior radiograph of neck of humerus taken erect to show fracture of the neck of the humerus

2- Axial or lateral

Position of Patient

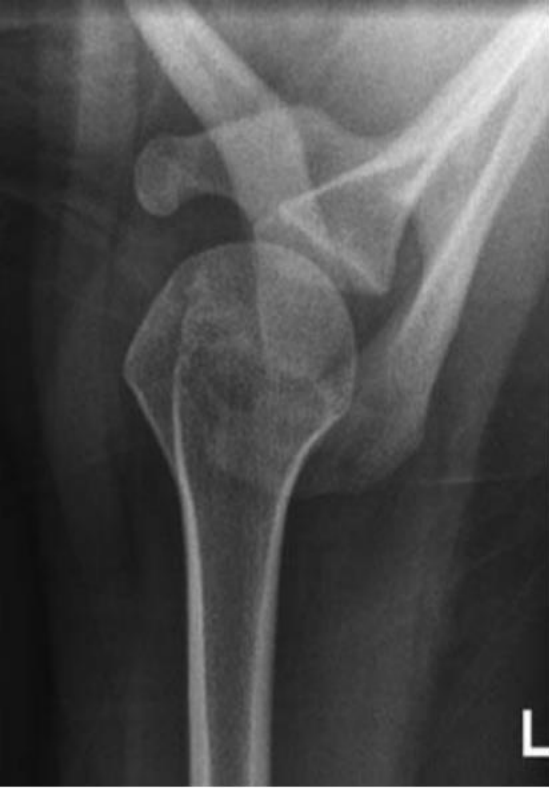- The patient is seated at one end of the table, with the trunk leaning towards the table, the arm of the side being examined in its maximum abduction, and the elbow resting on the table.
- The cassette out Bucky on the table between the elbow and the trunk.

Direction and Centering of the X-ray beam

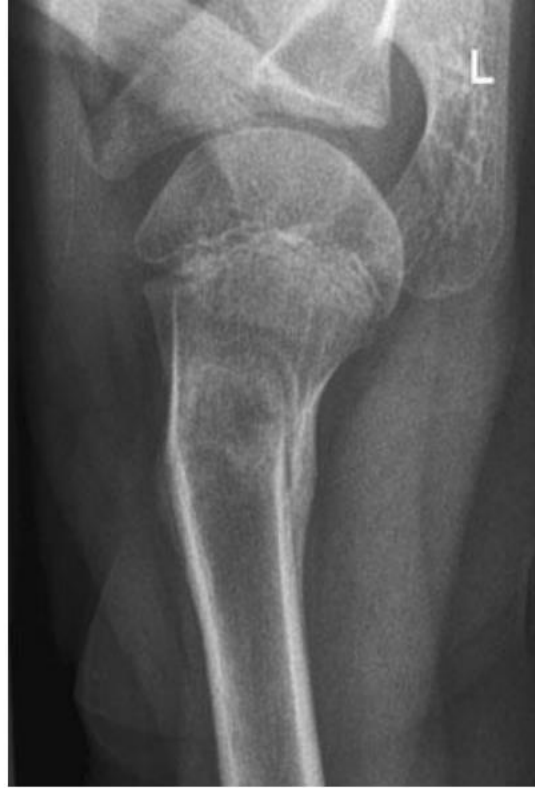- The vertical central ray is directed from above to the acromion process of the scapula.

Essential image characteristics

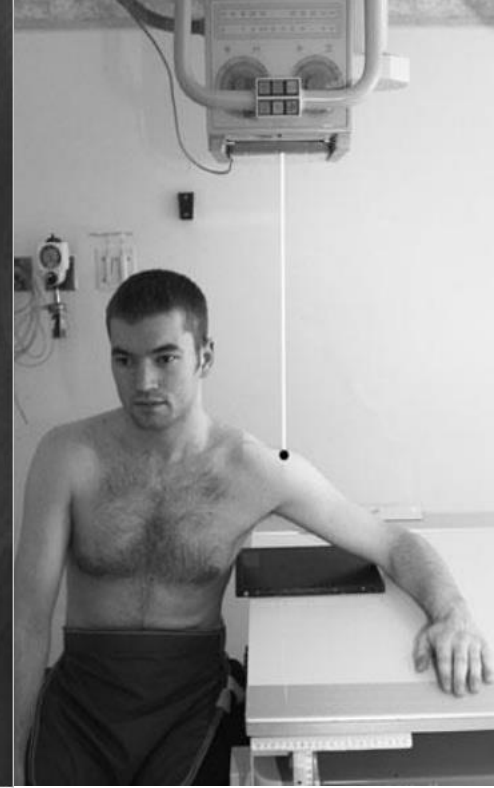- The image should include the acromion and coracoid processes, the glenoid cavity and the proximal head and neck of the humerus.
- The exposure should demonstrate adequately the neck of the humerus.



Normal superio-inferior projection to show neck of humerus



Superio-inferior projection for neck of humerus, showing healing angulated fracture of proximal shaft of humerus



Thanks

The word "Thanks" is written in a large, pink, cursive font with a sparkling, glitter-like texture. The text is centered and surrounded by decorative pink roses and green leaves on thin black stems. One rose is positioned above the letter 'h', another to the left of the 'T', and a larger one to the right of the 's'.